Arteries of the Head and Neck

Common Carotid Artery

The right common carotid artery arises from the brachiocephalic artery behind the right sternoclavicular joint. The left artery arises from the arch of the aorta in the superior mediastinum. The common carotid artery runs upward through the neck under cover of the anterior border of the sternocleidomastoid muscle, from the sternoclavicular joint to the upper border of the thyroid cartilage. Here, it divides into the external and internal carotid arteries

Carotid Sinus

At its point of division, the terminal part of the common carotid artery or the beginning of the internal carotid artery shows a localized dilatation, called the **carotid sinus**. The tunica media of the sinus is thinner than elsewhere, but the adventitia is relatively thick and contains numerous nerve endings derived from the glossopharyngeal nerve. The carotid sinus serves as a reflex pressoreceptor mechanism: A rise in blood pressure causes a slowing of the heart rate and vasodilatation of the arterioles.

Carotid Body

The carotid body is a small structure that lies posterior to the point of bifurcation of the common carotid artery. It is innervated by the glossopharyngeal nerve. The carotid body is a chemoreceptor, being sensitive to excess carbon dioxide and reduced oxygen tension in the blood. Such a stimulus reflexly produces a rise in blood pressure and heart rate and an increase in respiratory movements.
The common carotid artery is embedded in a connective tissue sheath, called the carotid sheath, throughout its course and is closely related to the internal jugular vein and vagus nerve

Clinical significance

Carotid Sinus Hypersensitivity

In cases of carotid sinus hypersensitivity, pressure on one or both carotid sinuses can cause excessive slowing of the heart rate, a fall in blood pressure, and cerebral ischemia with fainting.

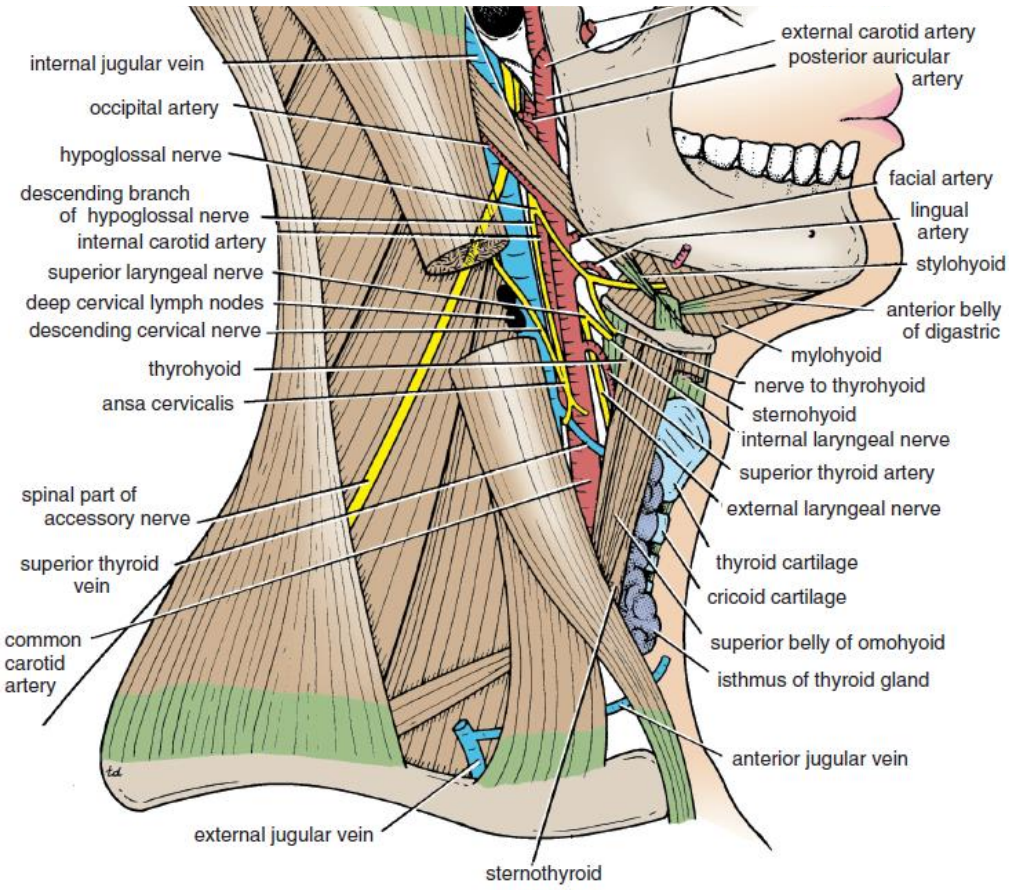

External Carotid Artery

The external carotid artery is one of the terminal branches of the common carotid artery. It supplies structures in the neck, face, and scalp; it also supplies the tongue and the maxilla. The artery begins at the level of the upper border of the thyroid cartilage and terminates in the substance of the parotid gland behind the neck of the mandible by dividing into the superficial temporal and maxillary arteries.

Close to its origin, the artery emerges from undercover of the sternocleidomastoid muscle, where its pulsations can be felt. At first, it lies medial to the internal carotid artery, but as it ascends in the neck, it passes lateral to it. It is crossed by the posterior belly of the digastric and the stylohyoid .

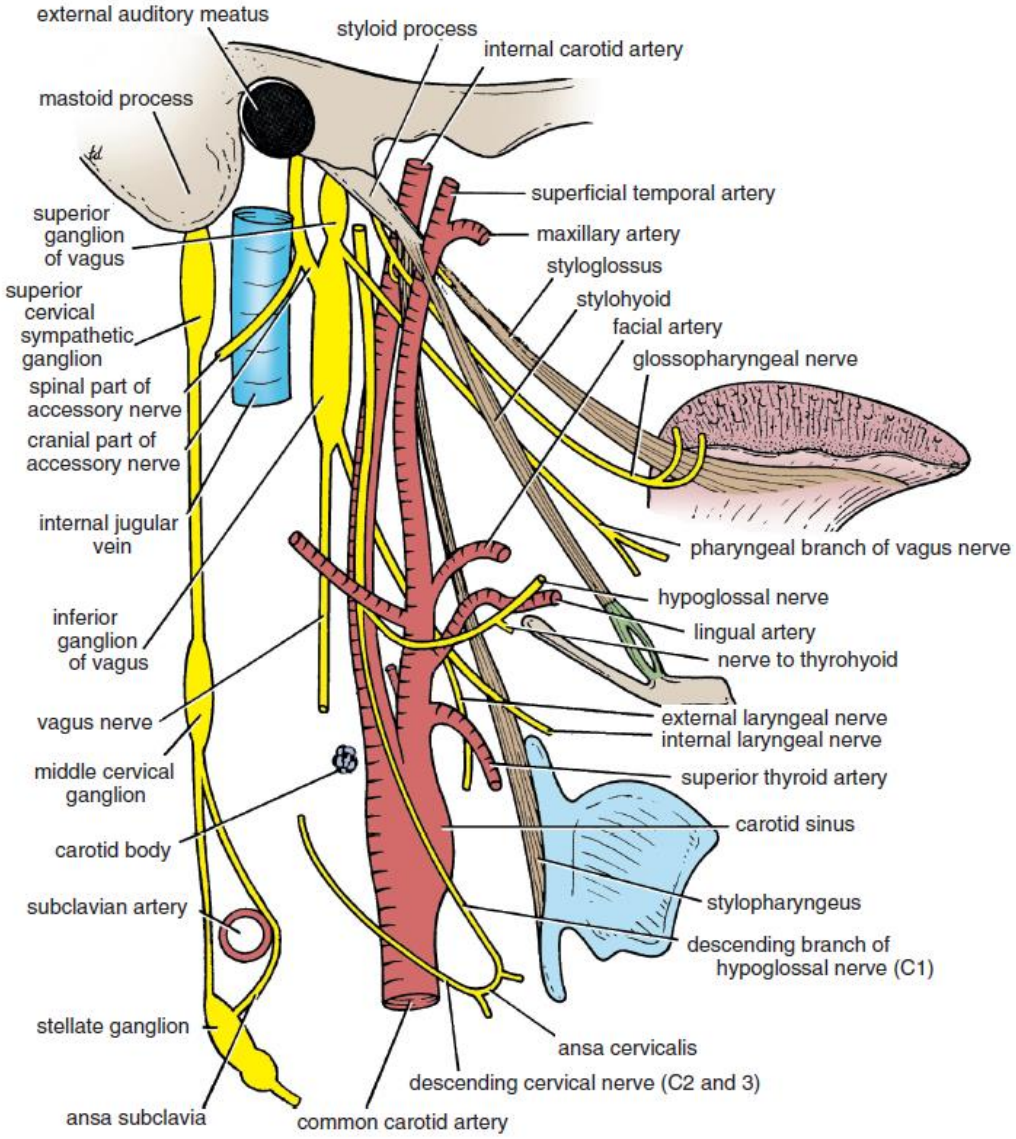

Branches of the External Carotid Artery

1. Superior thyroid artery
2. Ascending pharyngeal artery
3. Lingual artery
4. Facial artery
5. Occipital artery
6. Posterior auricular artery
7. Superficial temporal artery
8. Maxillary artery

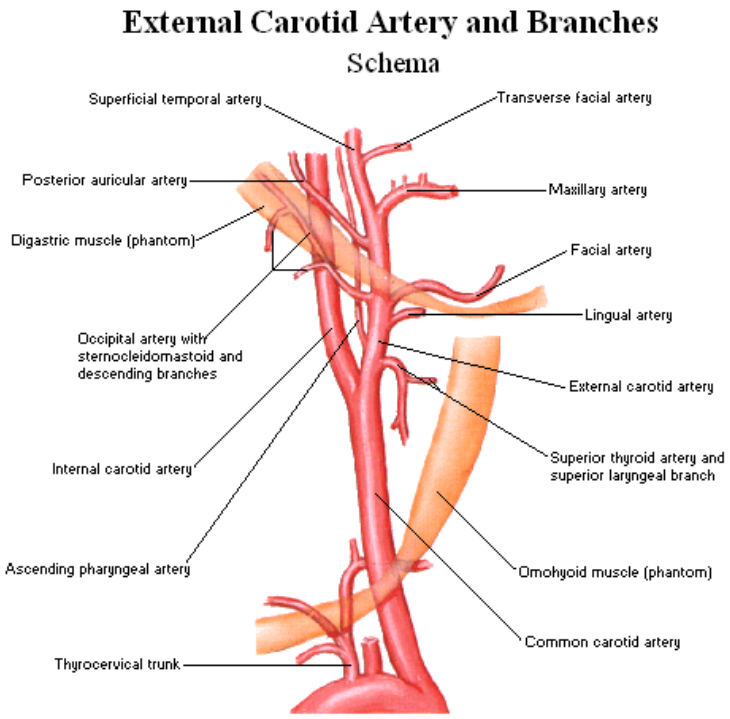

Superior Thyroid Artery

The superior thyroid artery curves downward to the upper pole of the thyroid gland. It is accompanied by the external laryngeal nerve, which supplies the cricothyroid muscle.

Ascending Pharyngeal Artery

The ascending pharyngeal artery ascends along and supplies the pharyngeal wall.

Lingual Artery

The lingual artery loops upward and forward and supplies the tongue.

Facial Artery

The facial artery loops upward close to the outer surface of the pharynx and the tonsil. It lies deep to the submandibular salivary gland and emerges and bends around the lower border of the mandible. It then ascends over the face close to the anterior border of the masseter muscle. The artery then ascends around the lateral margin of the mouth and terminates at the medial angle of the eye. Branches of the facial artery supply the tonsil, the submandibular salivary gland, and the muscles and the skin of the face.

Occipital Artery

The artery supplies the back of the scalp.

Posterior Auricular Artery

The posterior auricular artery supplies the auricle and the scalp.

Superficial Temporal Artery

The superficial temporal artery ascends over the Zygomatic arch, where it may be palpated just in front of the auricle. It is accompanied by the auriculotemporal nerve, and it supplies the scalp.

Maxillary Artery

The maxillary artery runs forward medial to the neck of the mandible and enters the pterygopalatine fossa of the skull.

Internal Carotid Artery

The internal carotid artery begins at the bifurcation of the common carotid artery at the level of the upper border of the thyroid cartilage. It supplies the brain, the eye, the forehead, and part of the nose. The artery ascends in the neck embedded in the carotid sheath with the internal jugular vein and vagus nerve. At first it lies superficially; it then passes deep to the parotid salivary gland.

The internal carotid artery leaves the neck by passing into the cranial cavity through the carotid canal in the petrous part of the temporal bone. It then passes upward and forward in the cavernous venous sinus (without communicating with it). The internal carotid artery then inclines backward, lateral to the optic chiasma, and terminates by dividing into the anterior and the middle cerebral arteries.

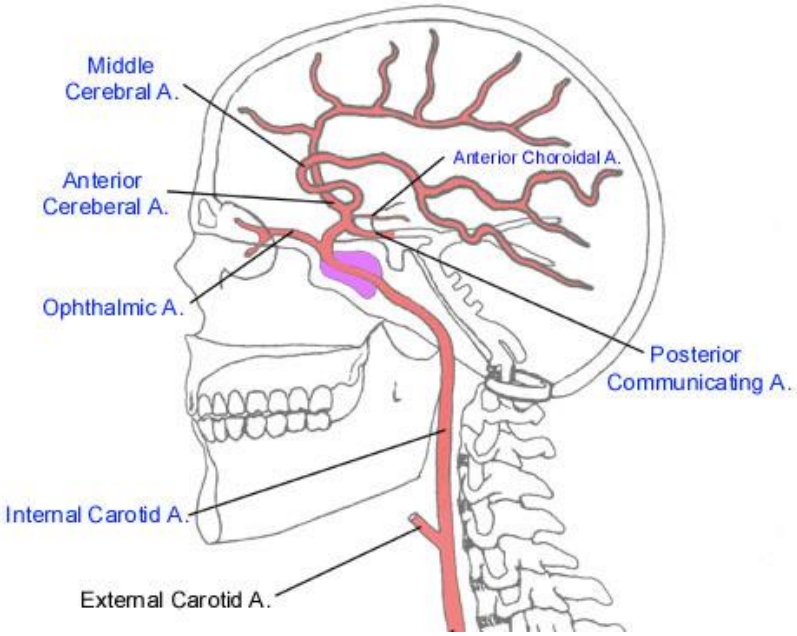

Cavernous Sinus

Coronal Section

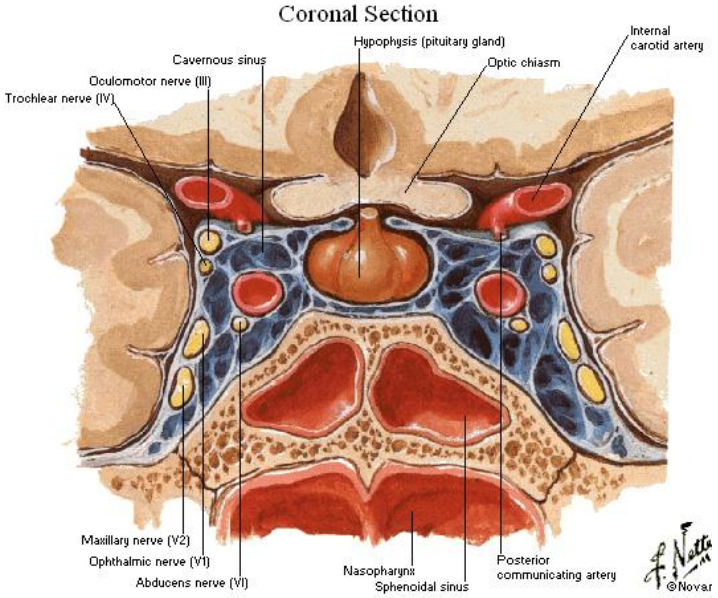

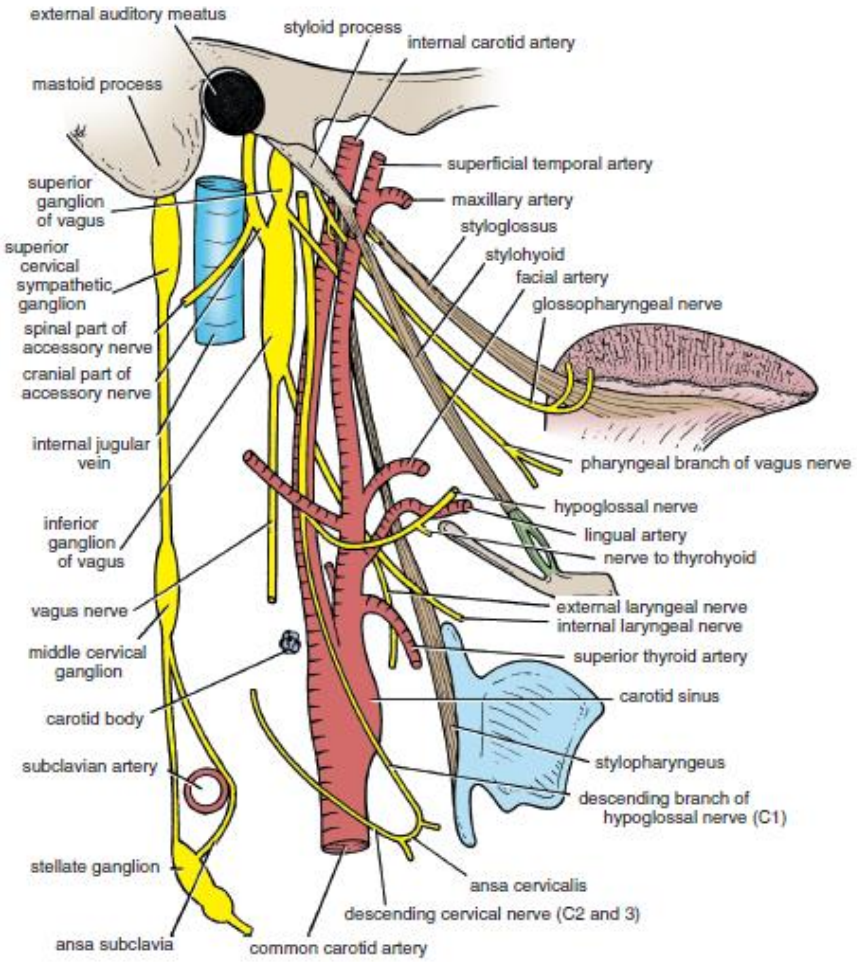

Branches of the Internal Carotid Artery

There are no branches in the neck. Many important branches, however, are given off in the skull.

1- Ophthalmic Artery

The ophthalmic artery arises from the internal carotid artery as it emerges from the cavernous sinus . It passes forward into the orbital cavity through the optic canal, and it gives off the central artery of the retina, which enters the optic nerve and runs forward to enter the eyeball. The central artery is an end artery and the only blood supply to the retina.

2- Posterior Communicating Artery

The posterior communicating artery runs backward to join the posterior cerebral artery.

3- Anterior Cerebral Artery

The anterior cerebral artery is a terminal branch of the internal carotid artery. It passes forward between the cerebral hemispheres and supply the medial and the superolateral surfaces of the cerebral hemisphere. It is joined to the artery of the opposite side by the **anterior communicating artery.**

4- Middle Cerebral Artery

The middle cerebral artery is the largest terminal branch of the internal carotid artery and it runs laterally in the lateral cerebral sulcus of the brain. It supplies the entire lateral surface of the cerebral hemisphere except the narrow strip along the superolateral margin (which is supplied by the anterior cerebral artery) and the occipital pole and inferolateral surface of the hemisphere (both of which are supplied by the posterior cerebral artery).

Subclavian Arteries

Right Subclavian Artery

The right subclavian artery arises from the brachiocephalic artery, behind the right sternoclavicular joint . It arches upward and laterally over the pleura and between the scalenus anterior and medius muscles. At the outer border of the 1st rib, it becomes the axillary artery.

Left Subclavian Artery

The left subclavian artery arises from the arch of the aorta in the thorax. It ascends to the root of the neck and then arches laterally in a manner similar to that of the right subclavian artery. The scalenus anterior muscle passes anterior to the artery on each side and divides it into three parts.

First Part of the Subclavian Artery

The first part of the subclavian artery extends from the origin of the subclavian artery to the medial border of the scalenus anterior muscle. This part gives off the vertebral artery, the thyrocervical trunk, and the internal thoracic artery.

Branches

1. The ***vertebral artery*** ascends in the neck through the foramina in the transverse processes of the upper six cervical vertebrae. hen ascends through the foramen magnum into the skull. On reaching the anterior surface of the medulla oblongata of the brain at the level of the lower border of the pons, it joins the vessel of the opposite side to form the basilar artery.

The **basilar artery** ascends in a groove on the anterior surface of the pons. It gives off branches to the pons, the cerebellum, and the internal ear. It finally divides into the two posterior cerebral arteries. On each side, the **posterior cerebral artery** curves laterally and backward around the midbrain.

Branches in the neck: Spinal and **muscular arteries**

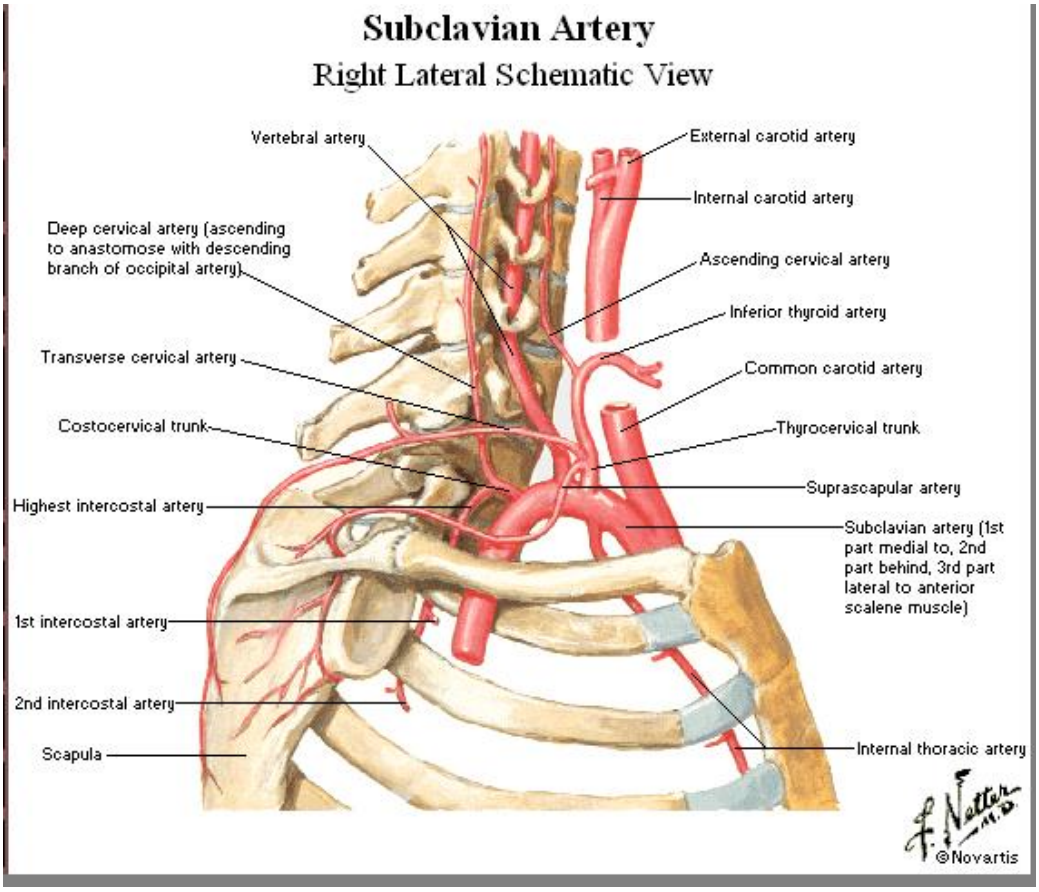

2. The **thyrocervical trunk** is a short trunk that gives off three terminal branches

A. The **inferior thyroid artery** ascends to the posterior surface of the thyroid gland, where it is closely related to the recurrent laryngeal nerve. It supplies the thyroid and the inferior parathyroid glands.

B. The **superficial cervical artery** is a small branch that crosses the brachial plexus.

C. The **suprascapular artery** runs laterally over the brachial plexus and follows the suprascapular nerve onto the back of the scapula.

3. The **internal thoracic artery** descends into the thorax behind the 1st costal cartilage and in front of the pleura. It descends vertically one fingerbreadth lateral to the sternum; in the 6th intercostal space, it divides into the superior epigastric and the musculophrenic arteries.

Second Part of the Subclavian Artery

The second part of the subclavian artery lies behind the scalenus anterior muscle.

Branches

The **costocervical trunk** runs backward over the dome of the pleura and divides into the **superior intercostals artery,** which supplies the 1st and the 2nd intercostal spaces, and the **deep cervical artery,** which supplies the deep muscles of the neck.

Third Part of the Subclavian Artery

The third part of the subclavian artery extends from the lateral border of the scalenus anterior muscle across the posterior triangle of the neck to the lateral border of the 1st rib, where it becomes the axillary artery. Here, in the root of the neck, it is closely related to the nerves of the brachial plexus.

Branches The third part of the subclavian artery usually has no branches.

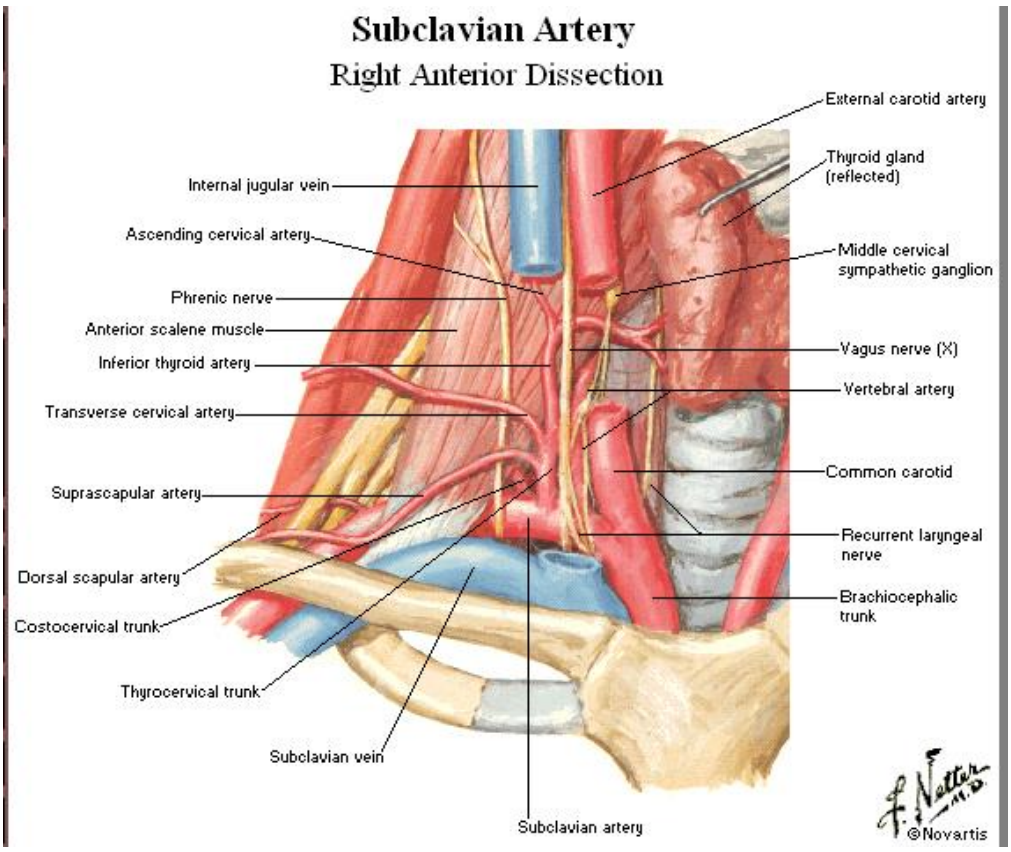

Circle of Willis

The circle of Willis lies in the subarachnoid space at the base of the brain. It is formed by the anastomosis between the branches of the two internal carotid arteries and the two vertebral arteries. The anterior communicating, anterior and posterior cerebral, and posterior communicating are all arteries that contribute to the circle. Cortical and central branches arise from the circle and supply the brain.

Arteries to Brain

Schema

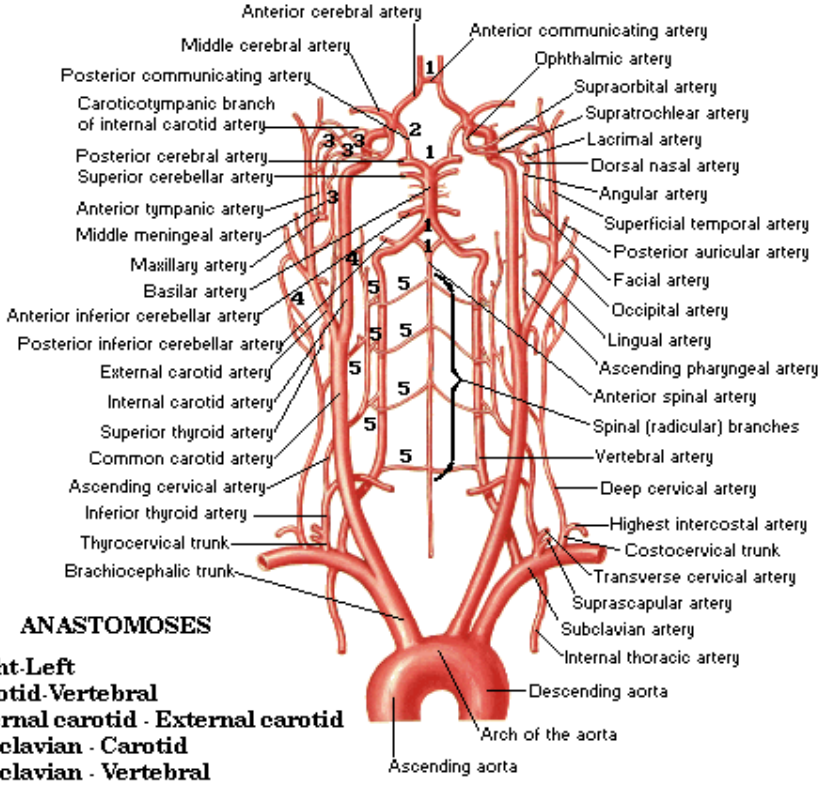

ANASTOMOSES

1. **Right-Left**
2. **Carotid-Vertebral**
3. **Internal carotid - External carotid**
4. **Subclavian - Carotid**
5. **Subclavian - Vertebral**